

Impact of View Ordering and Soft-Gating on Morphologic Assessment of Congenital Heart Disease with 4D Flow

Joseph Y Cheng^{1,2}, Kate Hanneman², Tao Zhang^{1,2}, Marcus T Alley², Peng Lai³, Jonathan I Tamir⁴, Martin Uecker⁴, Michael Lustig⁴, John M Pauly¹, and Shreyas S Vasanaawala²

¹Electrical Engineering, Stanford University, Stanford, CA, United States, ²Radiology, Stanford University, Stanford, CA, United States, ³Global MR Applications & Workflow, GE Healthcare, Menlo Park, CA, United States, ⁴Electrical Engineering and Computer Sciences, University of California, Berkeley, CA, United States

TARGET AUDIENCE: Radiologists & physicists interested in high-resolution cardiac imaging that includes function, anatomy, and flow.

PURPOSE: Volumetric time-resolved phase contrast MRI (4D flow) permits evaluation of congenital heart disease (CHD)^[1]. The ease of prescribing the scan and the ability to quantify function and flow make the technique compelling for CHD, and it can now be performed in relatively fast scan times (3-10 min). However, a comprehensive CHD exam must also assess anatomy, particularly for complex CHD. Therefore, we evaluate the performance of a compressed sensing motion-corrected 4D flow technique with ferumoxytol by assessing anatomy.

METHOD: With IRB approval and informed assent/consent, 23 consecutive patients (15 males and 8 females, mean: 6.3 yrs, range: 2 days – 22.1 yrs) were recruited and imaged on a GE MR750 3T scanner (Waukesha, WI). The protocol consisted of ferumoxytol enhanced 4D flow imaging scan: unbalanced minimum echo time flow-encoding^[2] in a cardiac gated 3D Cartesian SPGR sequence with a 32ch-cardiac coil. Scan parameters include flip angle of 15°, resolution of 0.8x0.8x1.4 mm³, TE of 1.8 ms, TR of 9.1 ms (with fat-saturation), and bandwidth of ±83.33 kHz. Two 4D flow imaging scans were performed (reduction factors 16-27):

1. A control scan using Variable-Density Poisson disc sampling (VDPoisson)
2. A Variable-Density sampling and Radial view-ordering scan (VDRad^[3]).

The total scan time for VDPoisson was 6.1-11.3 min and for VDRad was 6.2-11.6 min. Butterfly^[4] navigators were used in the VDRad scan to monitor respiratory motion.

Image reconstruction: Several variations of compressed sensing^[5] and parallel imaging (with ESPIRiT^[6,7]) algorithms were used to reconstruct 20 cardiac phases:

- A. Spatial sparsity with Wavelets and VDPoisson (Wav & VDPoisson),
- B. Included total variation (TV) for the cardiac dimension (WavTV & VDPoisson),
- C. Used VDRad instead of VDPoisson (WavTV & VDRad), and
- D. Included soft-gating^[3] with TV and VDRad (SGWavTV & VDRad).

Image evaluation: Two cardiovascular imagers independently evaluated the reconstructed images according to the following features: 1) overall image quality, 2) motion ghosting, 3) hepatic vessels, 4) aortic and 5) tricuspid valves, and 6) coronary arteries on a scale of 1 (nondiagnostic) to 5 (excellent). To evaluate the effect of motion compensation using soft-gating, a paired assessment between reconstruction C (WavTV & VDRad) and D (SGWavTV & VDRad) was performed for the same 6 features. The paired Wilcoxon test was used to test the null hypothesis that there were no significant differences between the different reconstructions ($P < 0.05$ is considered statistically significant). Inter-observer agreement was evaluated using weighted kappa coefficient. Since it was unclear which method would yield the most accurate results, internal controls were used to evaluate flow.

RESULTS: The inclusion of additional components resulted in incremental improvements in diagnostic quality of the different features. By including all components (VDRad + TV + soft-gating in D), the features were better with statistical significance (Fig. 2). Both readers evaluated the soft-gated version of the same scan to be better than the non-soft-gated version with $P < 0.05$ (Fig. 1). For all image assessment results, both readers were in moderate to almost perfect agreement. Excluding patients with shunts, the flow analysis demonstrated the accuracy of the flow quantification with internal controls being unbiased ($BA < 0.02\%$) and highly correlated ($\rho > 0.85$) as described in Table 1.

DISCUSSION: Contrast enhancement with ferumoxytol enabled the comparison of two back-to-back high-resolution acquisitions with no noticeable change in contrast. Anatomical features were better delineated with VDRad and further improved by motion correction (D). The additional CS component with soft-gating did not significantly impact flow quantification. This is the first description of the use of 4D flow for structural assessments in CHD. With the addition of these morphologic capabilities, 4D flow can provide a single rapid comprehensive assessment of flow, function, and anatomy for CHD.

REFERENCES: [1] A Hsiao et al. AJR, 198:W250-259 (2012). [2] MA Bernstein et al. JMRI, 2:583-588 (1992). [3] JY Cheng et al. JMRI doi: 10.1002/jmri.24785 (2014). [4] JY Cheng et al. MRM, 68:1785-1797 (2012). [5] M Lustig et al. MRM, 58:1182-1195 (2007). [6] M Uecker et al. MRM, 71:990-1001 (2014). [7] bart. v0.2.04. (2014) doi: 10.5281/zenodo.12495

Child Health Research Institute, Lucile Packard Foundation for Children's Health (UL1 TR001085), NIH R01 EB009690, Sloan Research Fellowship

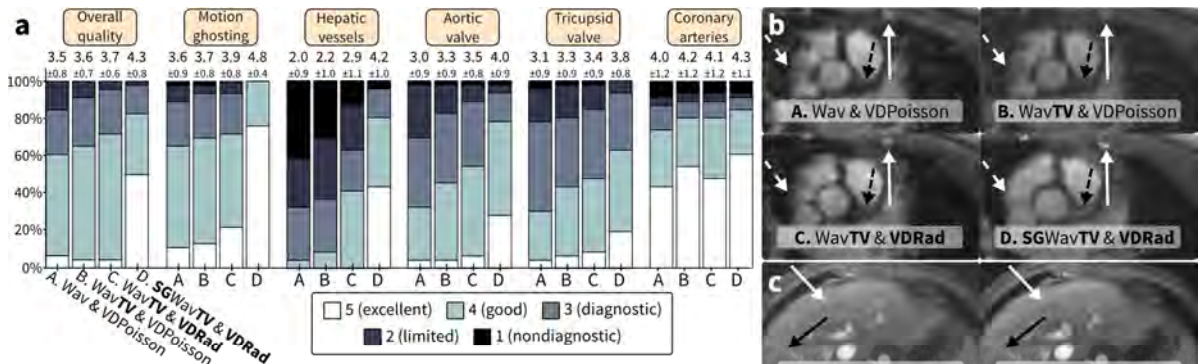


FIG. 2: Image assessment results and representative images. a: Each color bar represents the % of cases with the same score from either reader; mean ± standard deviation is annotated above each bar. b: 8 yr male with sharpened left coronary artery (dashed black) and cardiac wall (dashed white). c: 3.8 yr male with recovered fine hepatic vessels (arrows) and reduction of motion ghosting. The different reconstructions resulted in majority of cases to be of diagnostic quality. There was a significant improvement ($P < 0.05$) for recon D over others for most features. Features sensitive to respiratory motion (motion ghosting, hepatic vessels) were best when soft-gating was applied.

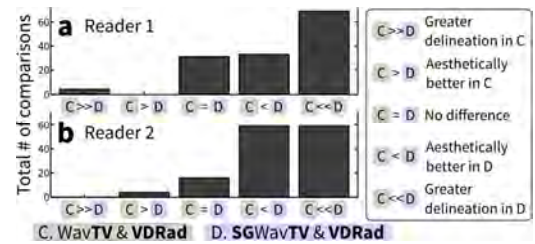


FIG. 1: Paired assessment between recon C (WavTV & VDRad) and D (SGWavTV & VDRad) to evaluate the impact of soft-gating. a: Total # of comparisons for Reader 1 for all features. b: Reader 2. With $P < 0.05$ and moderate to almost perfect agreement, both readers prefer the soft-gated reconstruction over the non-soft-gated variant. There was an outlier case where C was better; this is most likely because too much data was discarded when motion is considered. A slightly longer scan time may have been necessary.

Table 1: Flow analysis using Morpheus (San Francisco, CA).

	Aortic = pulmonary (PA) flow		PA flow: main = RPA + LPA	
	Bland-Altman mean ± 1.96std	Pearson corr (ρ)	Bland-Altman mean ± 1.96std	Pearson corr (ρ)
A	-0.02% ± 0.25%	0.95	0.01% ± 0.17%	0.97
B	0.00% ± 0.31%	0.91	-0.02% ± 0.17%	0.96
C	-0.02% ± 0.32%	0.85	0.01% ± 0.24%	0.98
D	0.01% ± 0.38%	0.89	0.00% ± 0.23%	0.97